ORAL PATHOLOGY

Developmental defects of the soft tissue

DR.NOOR

LAB. 14

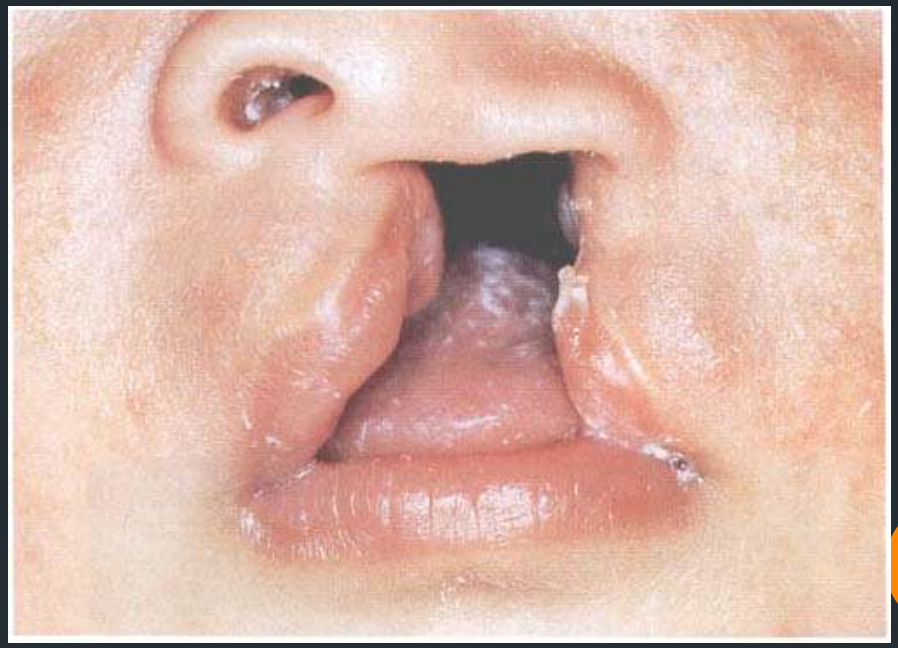

c

Cleft lip and Cleft palate

Generally, clefts of the lip and palate are classified into four major types:

- cleft lip.
- cleft palate.
- unilateral cleft lip and palate.
- bilateral cleft lip and palate.

A

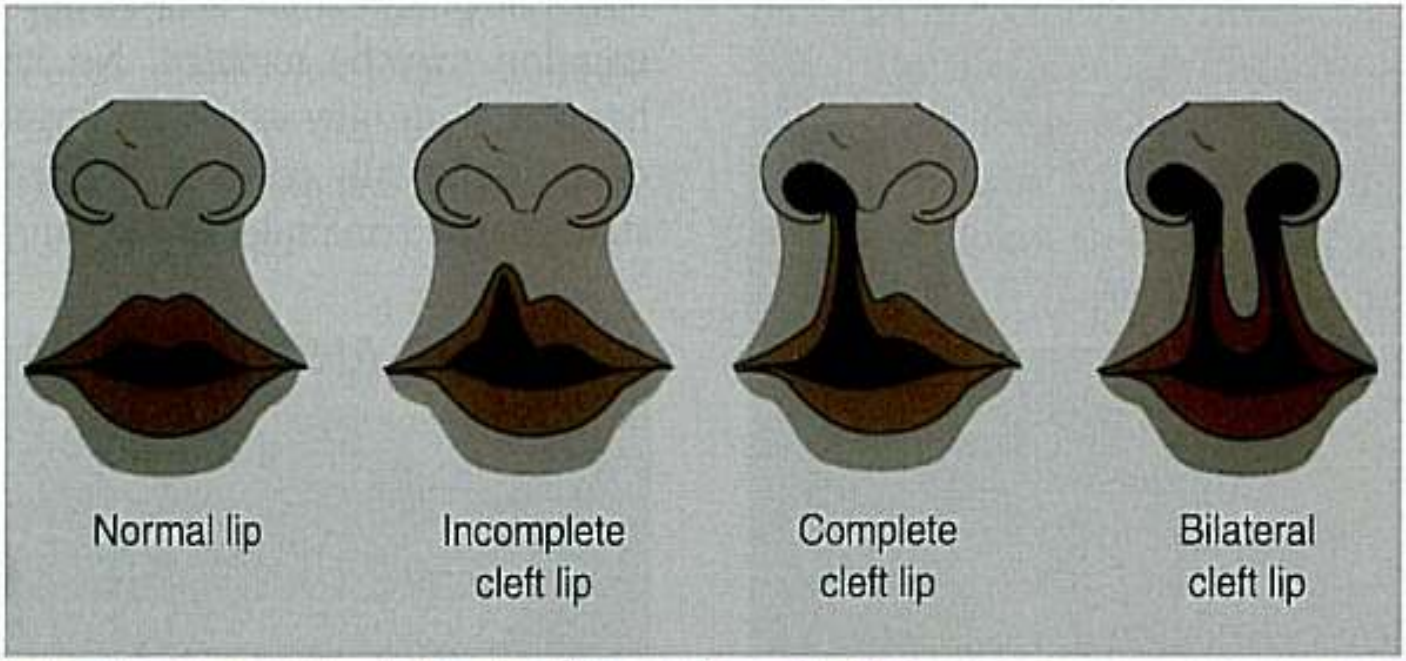
Normal lip
Incomplete cleft lip
Complete cleft lip
Bilateral cleft lip

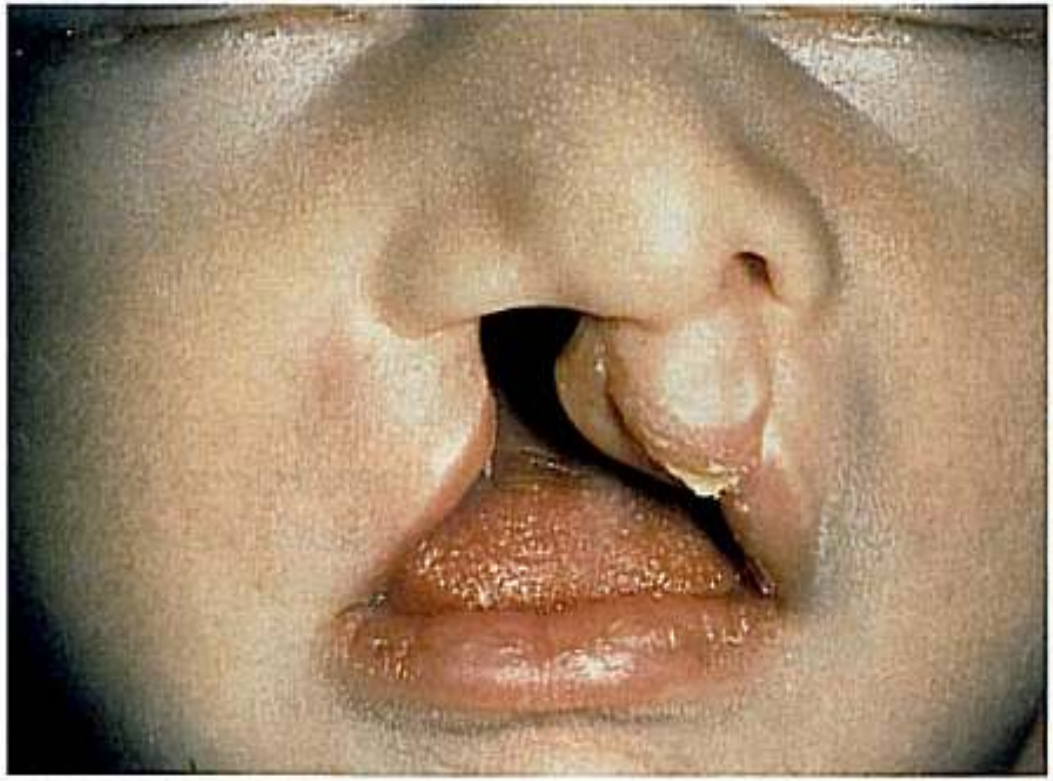

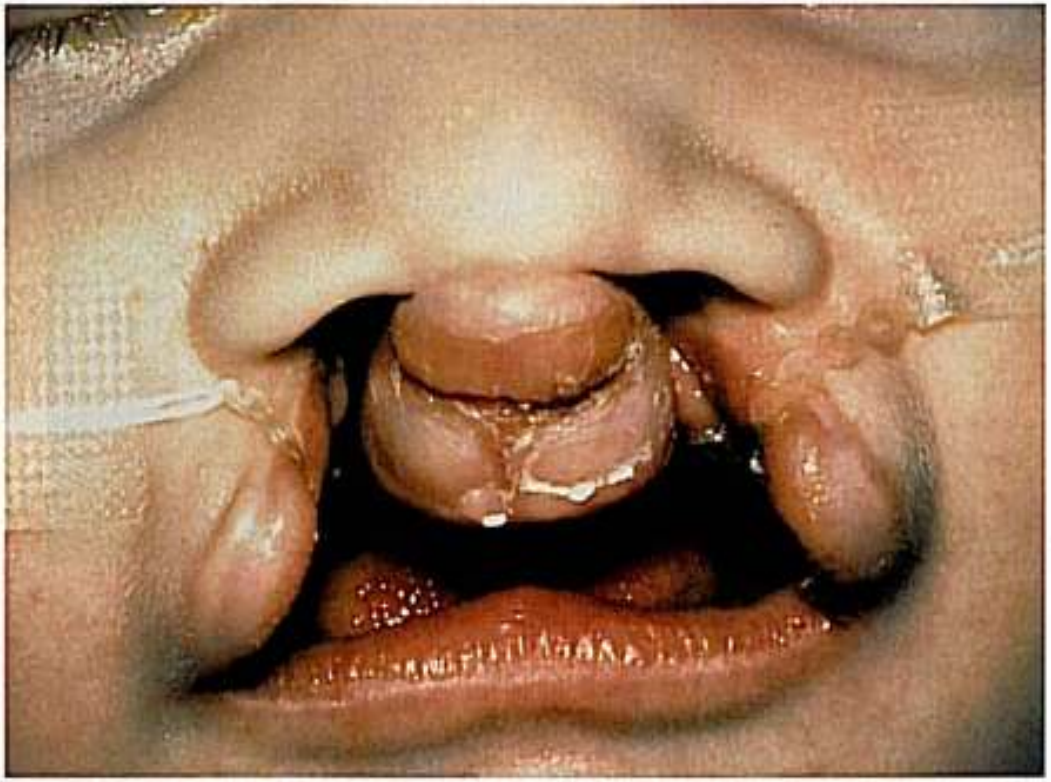

Submucous palatal deft. There is a cleft of the midline palatal bone. but the overlying mucosa is intact. A bifid uvula also is present.

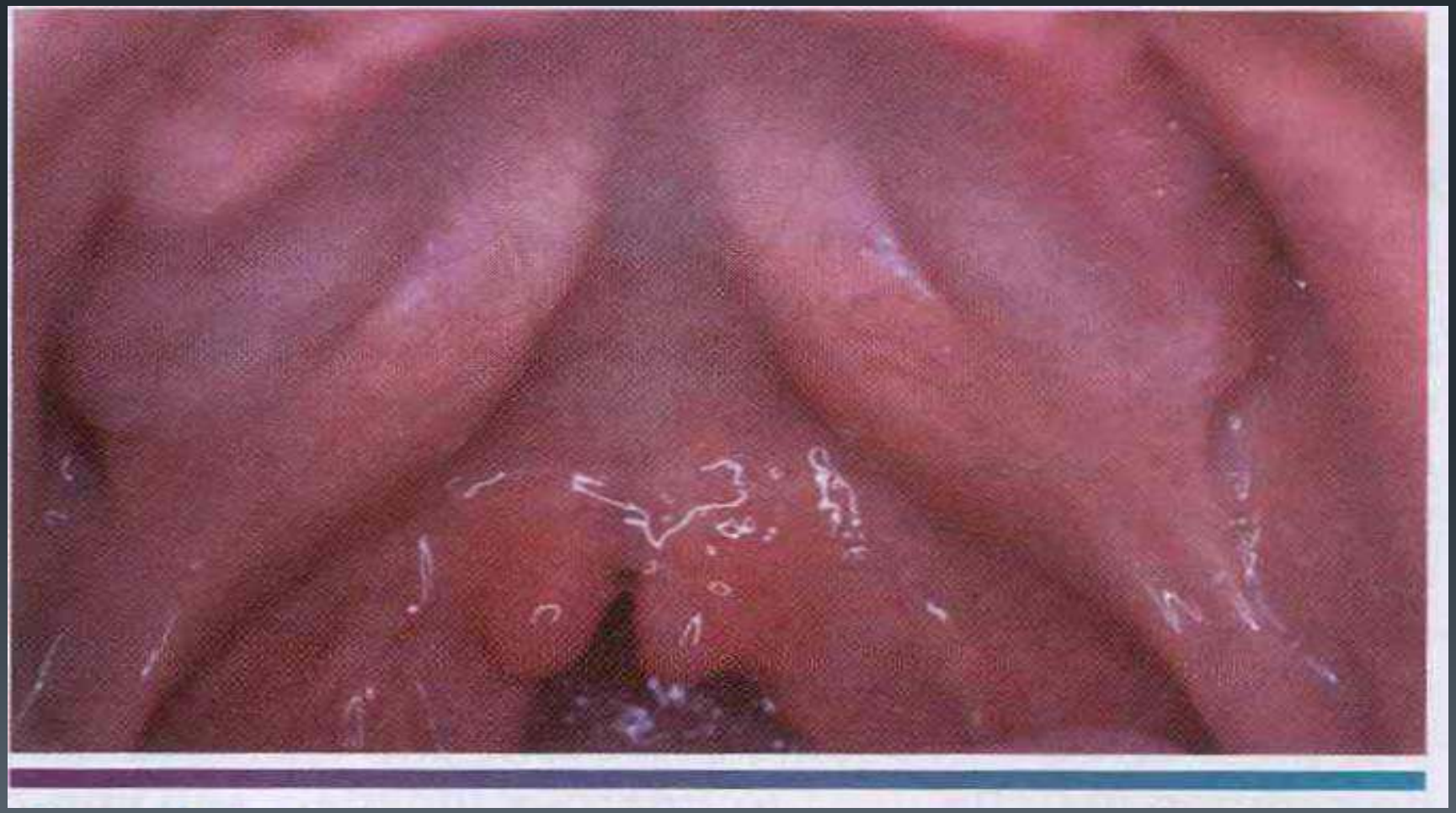

Cleft palate. Palatal defect resulting in communication with the nasal cavity.

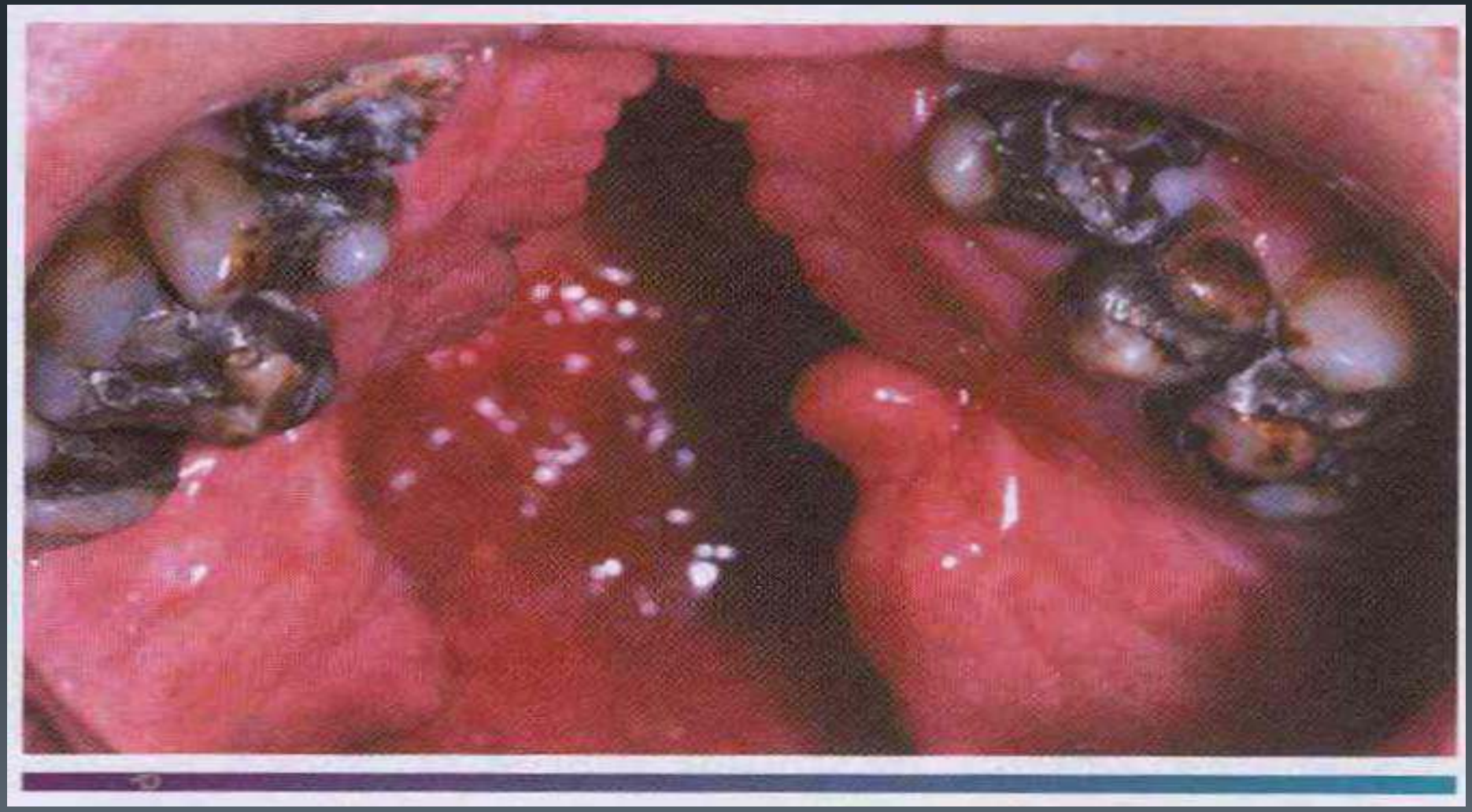

Cleft (bifid) uvula.

The Pierre Robin syndrome

- characterized by CP, mandibular micrognathia and glossoptosis: *(airway obstruction caused by lower posterior displacement of the tongue) .*

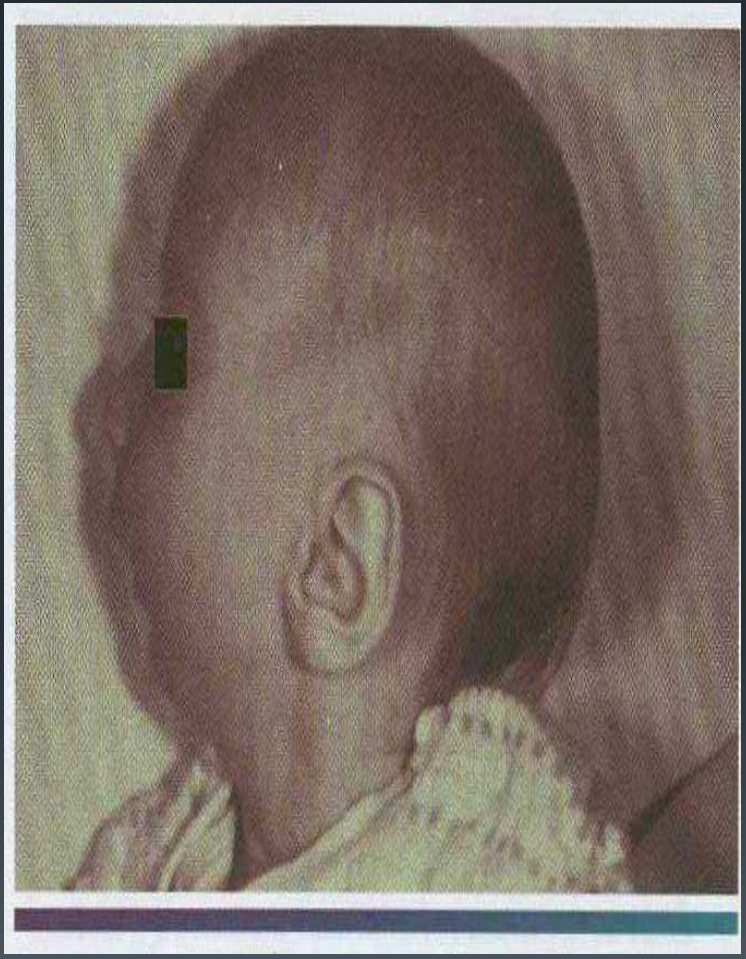

Congenital lip pits:

- ***(paramedian lip pit) :*** developmental defects that may involve the paramedian portion of the vermillion of the lower and upper lip.
- ***(commissural lip pit) :*** developmental defects that may involve the labial commissure area.
- The paramedian lip pits are occasionally **excised** for cosmetic reasons.
- commissural lip pits required no treatment.

FIGURE 1-48

Congenital lip pit. A, An orifice of a lip pit is present in the angle (commissure) of the lips. **B,** Photomicrograph of removed lip pit that had become cystic. A layer of squamous epithelium lines the blind pouch, and the lumen is filled with desquamated epithelial cells.

Commissural lip pit.

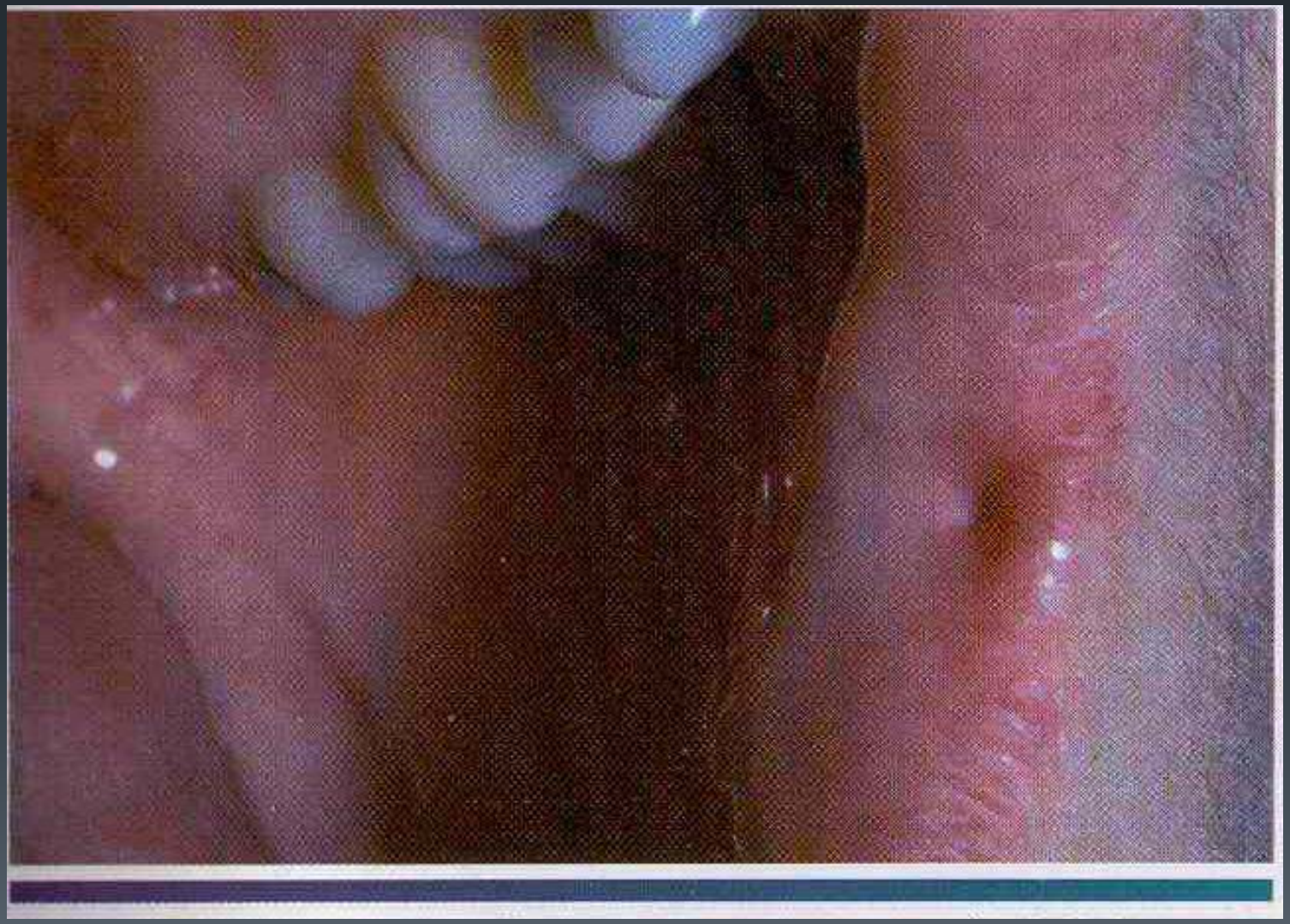

Paramedian lip pits. Bilateral pits on the lower lip in a patient with ***Van Der Woude syndrome.***

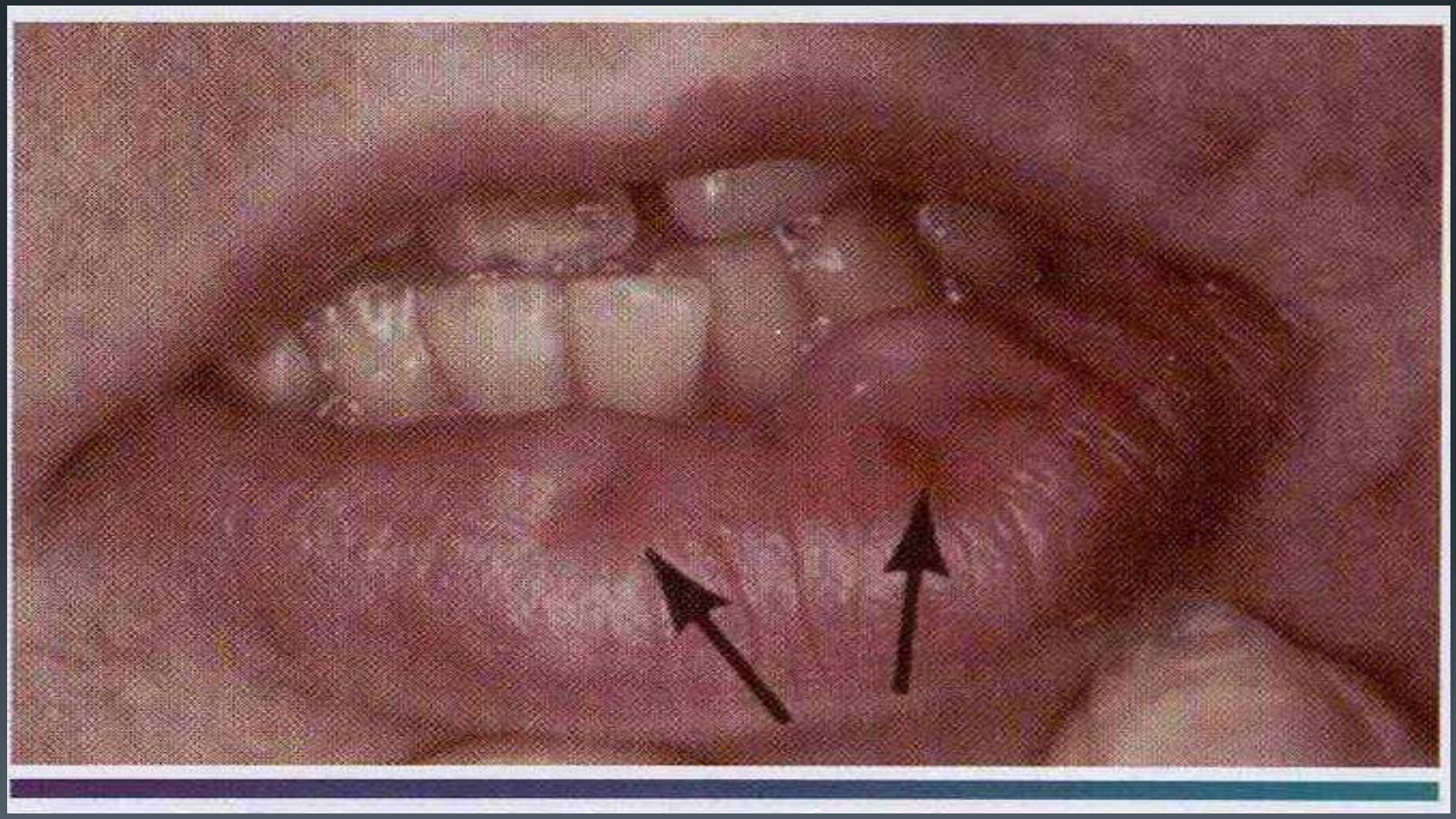

Double lip:

- A double lip is an anomaly characterized by a horizontal fold of mucosal tissue that is usually located on the inner aspect of the upper lip.
- This tissue can be congenital or acquired.
- Although this redundant fold of tissue is occasionally excised for cosmetic reasons, double lip usually requires no treatment.

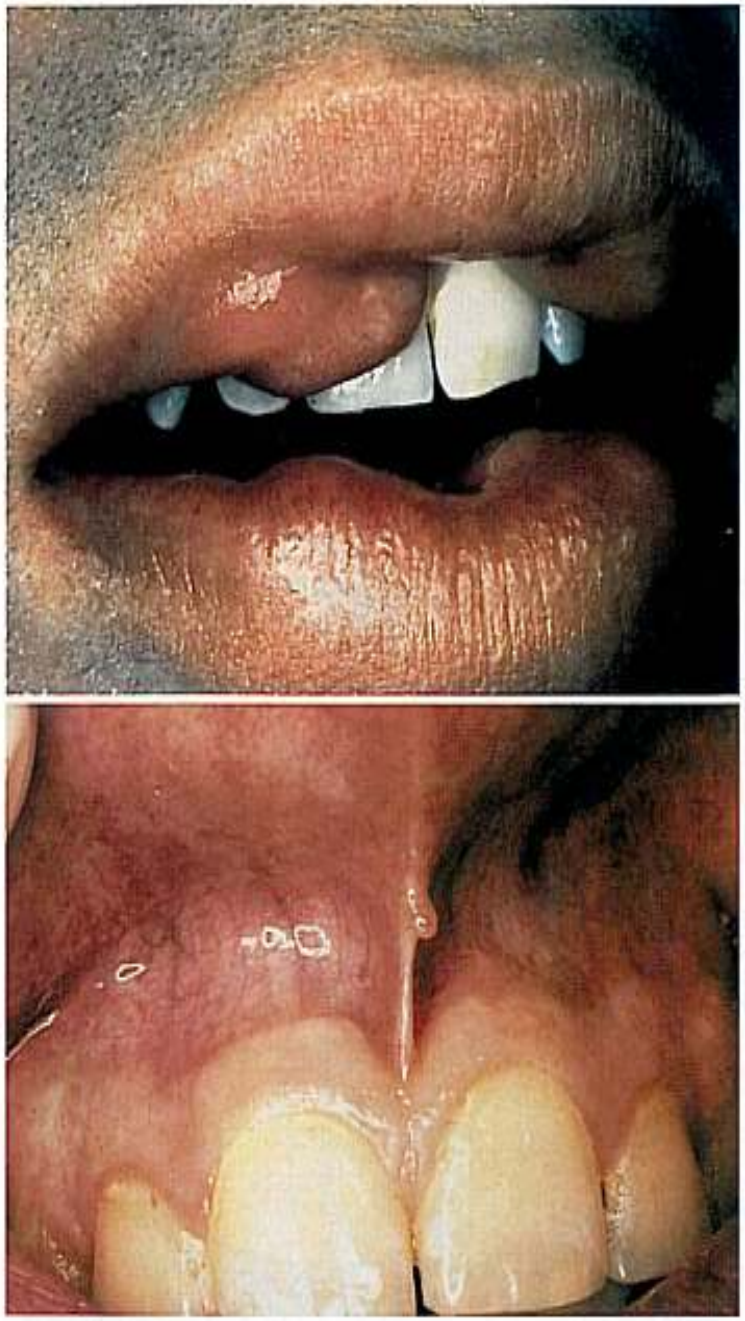

FIGURE 1-49
A, Double lip phenomenon involving both upper and lower lips. **B,** Frenal tag involving the maxillary labial frenum in a teenage female.

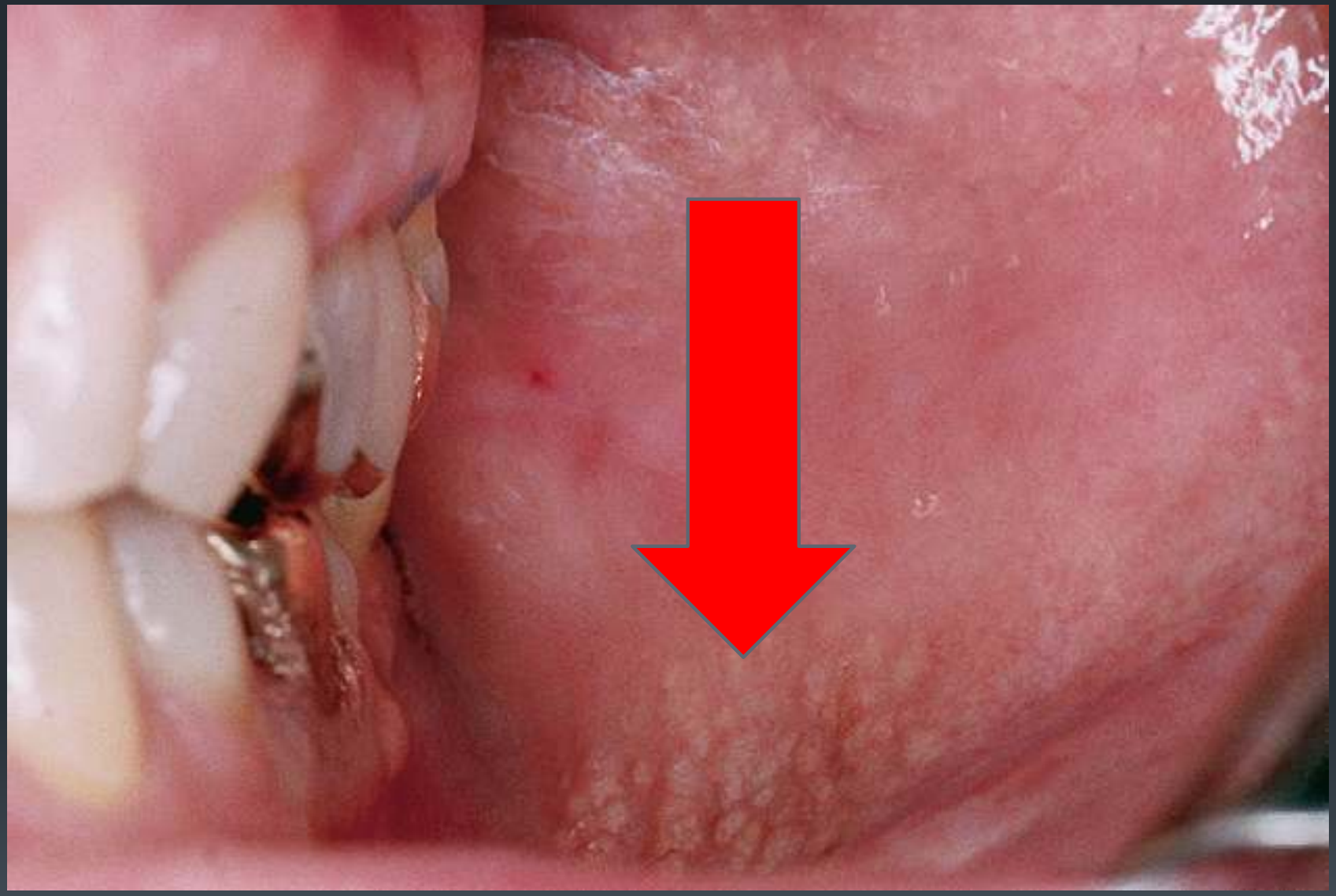

Fordyce's Granules

- ***Microscopically***, lobules of sebaceous glands are aggregated around or adjacent to excretory ducts.
- ***No treatment*** is indicated for this particular condition because the glands are normal in character.

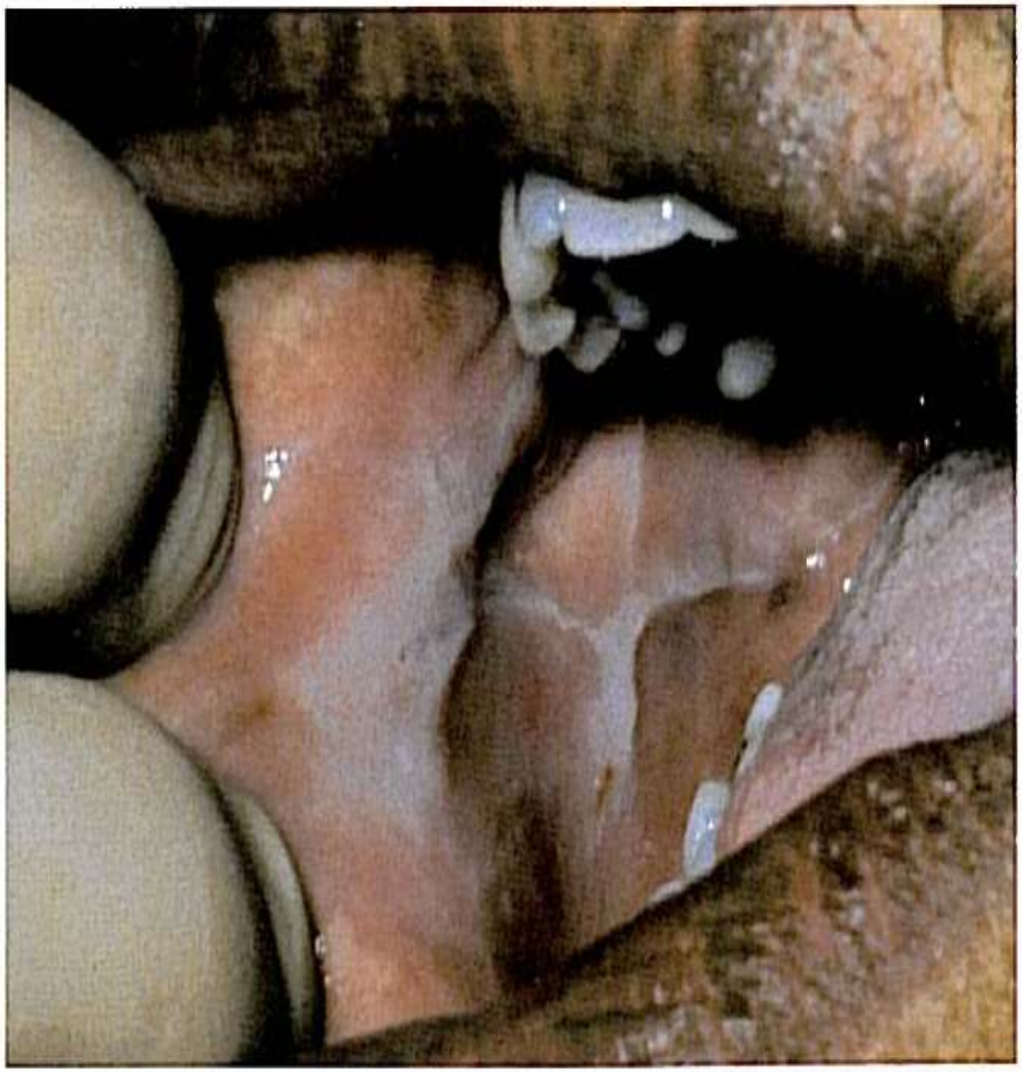

FIGURE 1-53

Leukoedema. Buccal mucosa of the patient exhibits an asymptomatic white-gray superficial layer that does not rub off.

Histopathology: In leukoedema:

- the epithelium is parakeratotic and acanthotic, with **marked intracellular edema of spinous cells.**
- The enlarged epithelial cells have small, pyknotic (condensed) nuclei in optically clear cytoplasm.

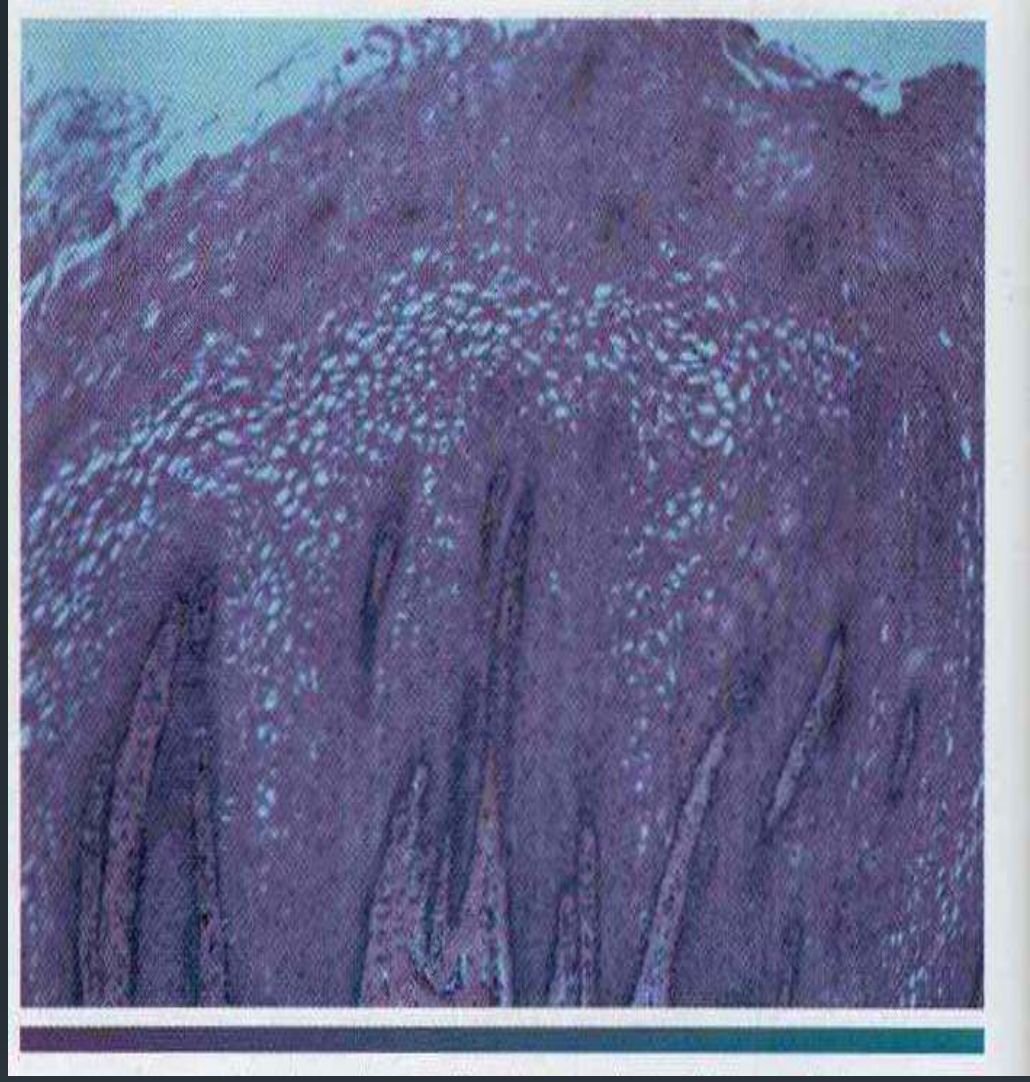

Differential Diagnosis:

- White sponge nevus.
- Hereditary benign intraepithelial dyskeratosis.
- The response to chronic cheek biting.
- Lichen planus may show clinical similarities to leukoedema.

Treatment and Prognosis: Treatment is not necessary

White sponge nevus:

- uncommon, autosomal dominant hereditary disorder that manifests as a white lesion of the oral mucosa.
- some patients exhibit lesion at birth, whereas in others, lesions may not appear until early childhood or even adolescence.

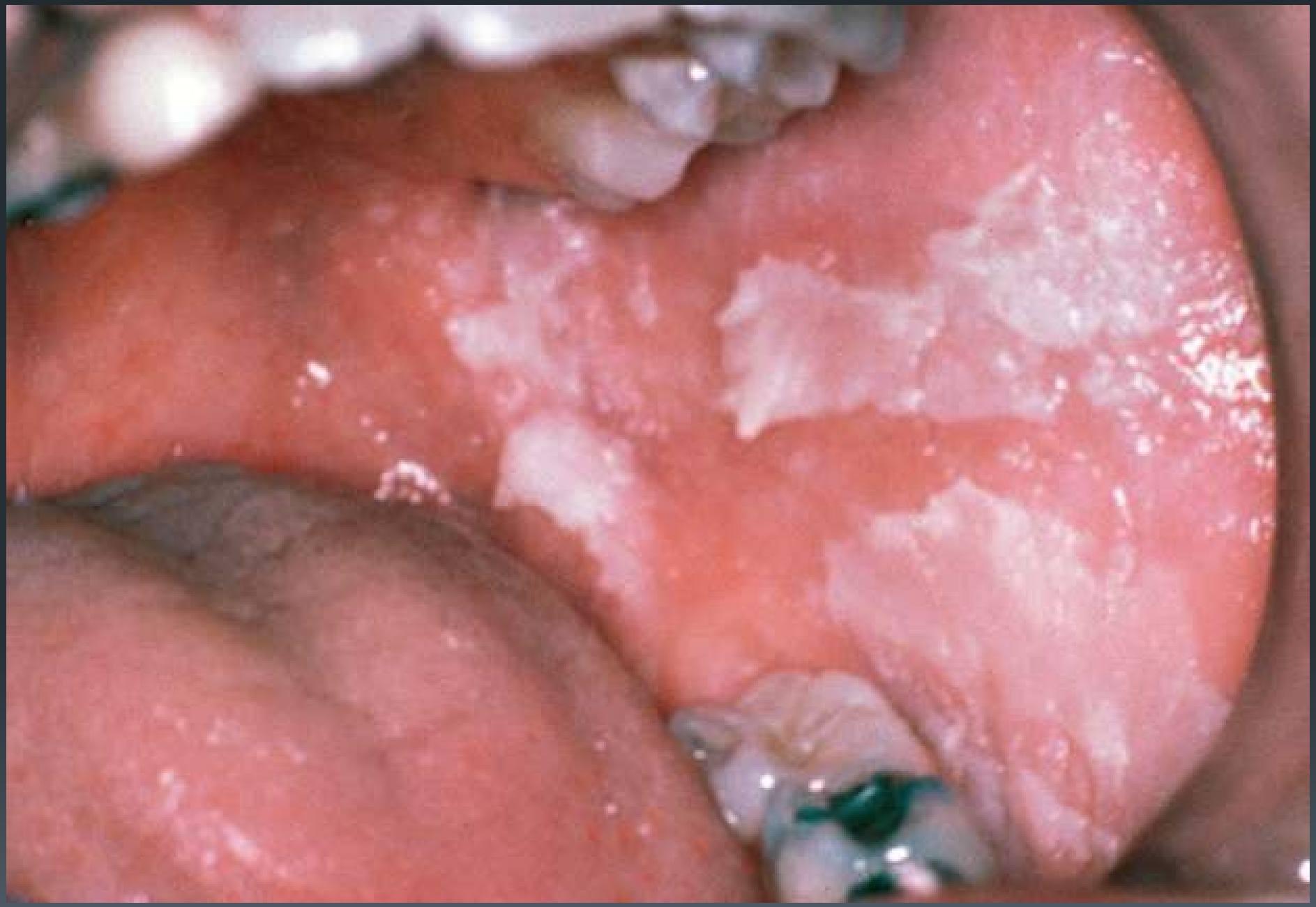

Histopathology: a mild to moderate hyperparakeratosis, acanthosis , and intracellular edema of the **spinous cells are shrunken (pyknotic).**

The associated connective tissue is usually free of inflammation. The diagnosis is generally reached by combining its histopathologic features, clinical appearance, and the patient's family history

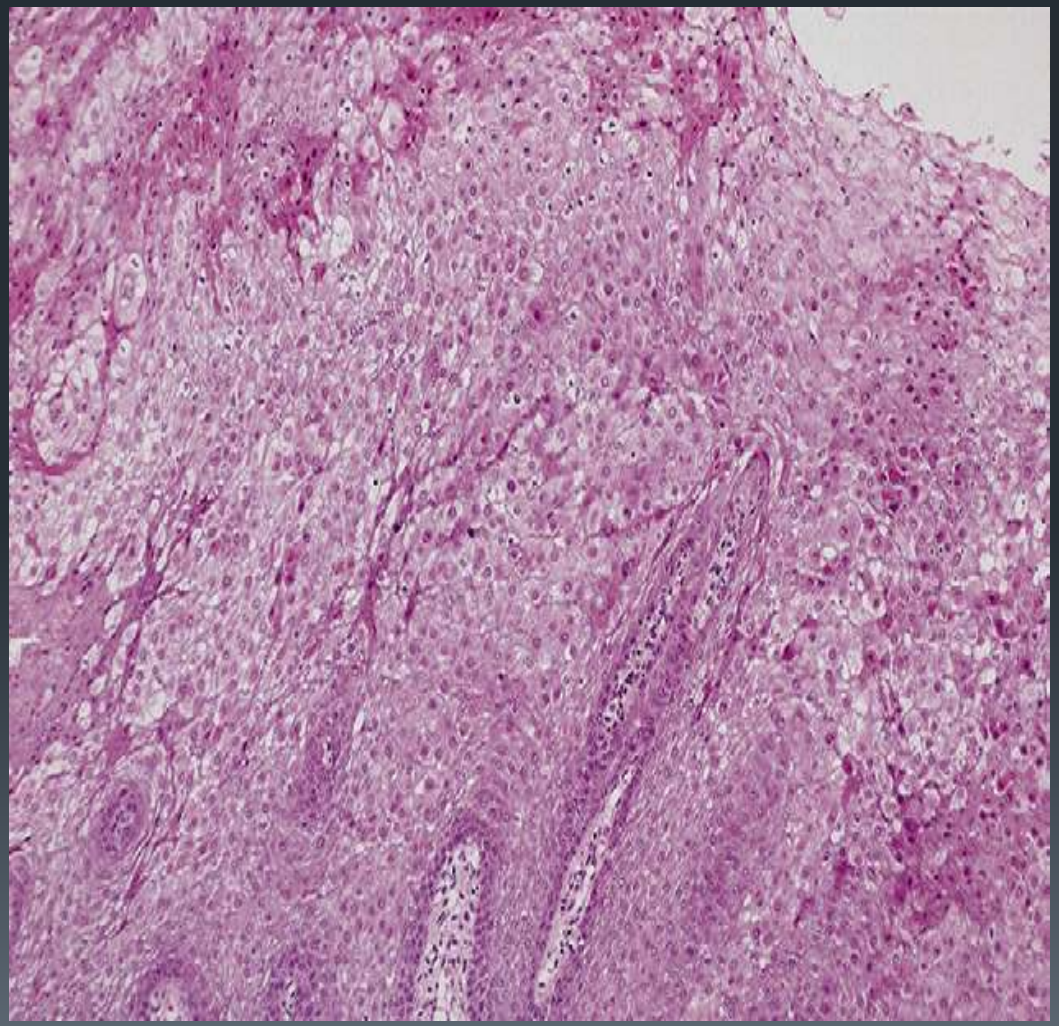

- **Oral tonsil:**
- In children and adolescents, tonsillar tissue may also be visible as discrete ,**slightly elevated reddish papules in the f bor of the mouth on either side of lingual frenum** .
- **These islands of extrapharyngeal of tissue are termed oral tonsils.**

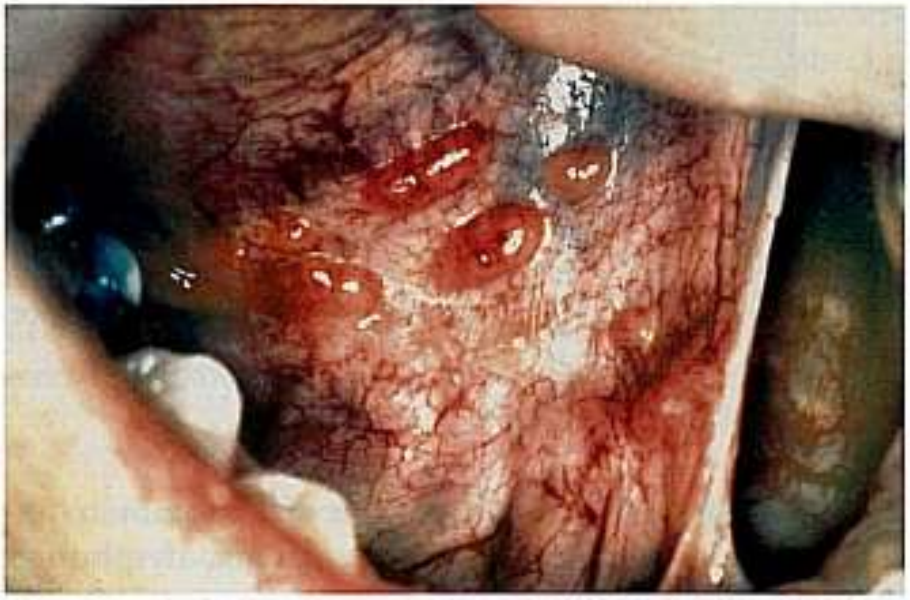

FIGURE 1-56
Oral tonsil presenting as slightly raised mucosal plaques on the anterior floor of the mouth.

Ectopic lymphoid tissue, floor of mouth.

Reterocuspeid papilla:

- .

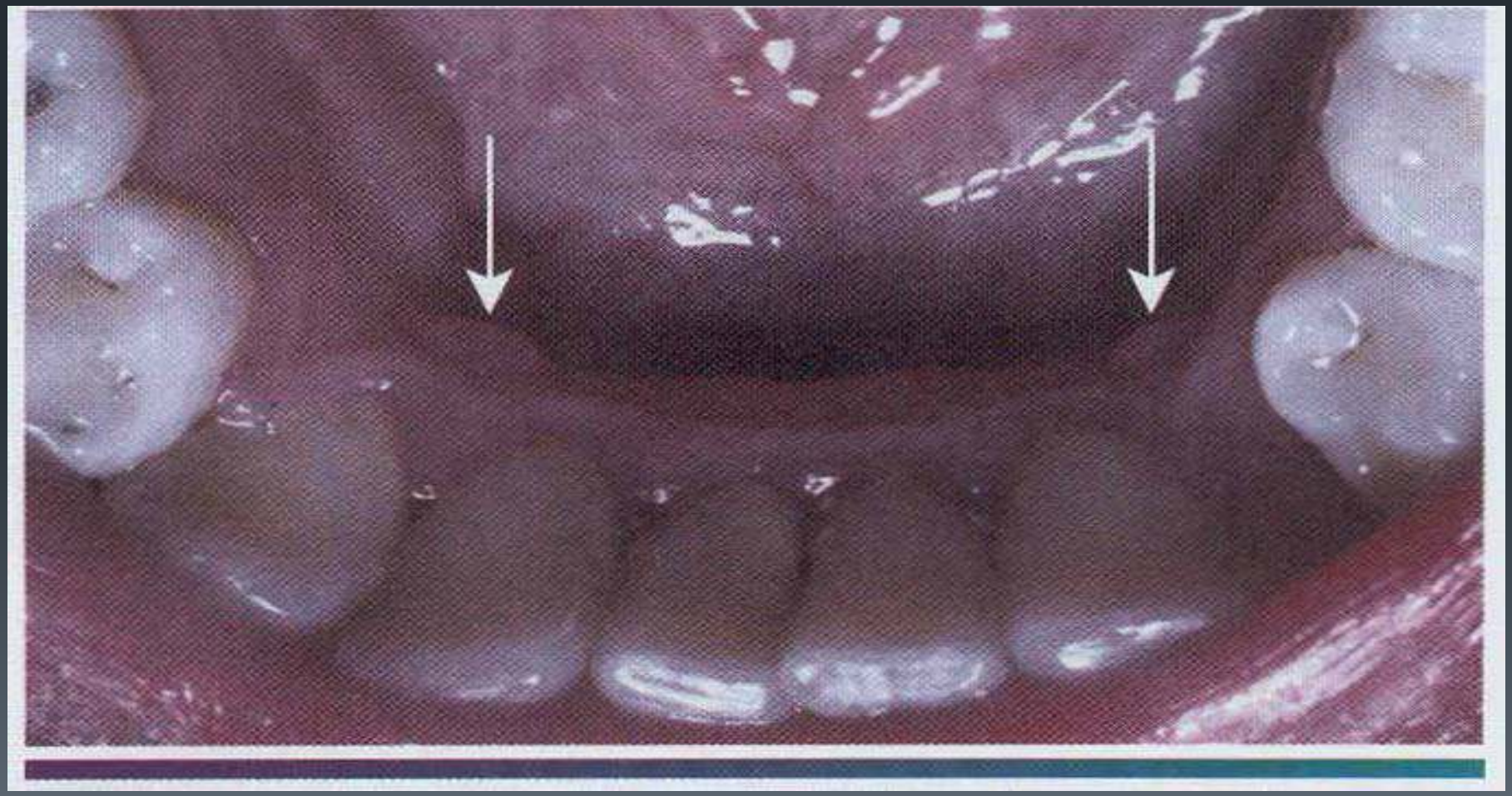

- **Histologically**,
- Gross anatomic examination of human mandible suggests that the reterocuspid papilla is **analogous to an incisive papilla**, representing a focus of f brovascular tissue covering the osseous foramen of a nutrient blood vessel.

Abnormally small tongue associated with constricted mandibular arch.

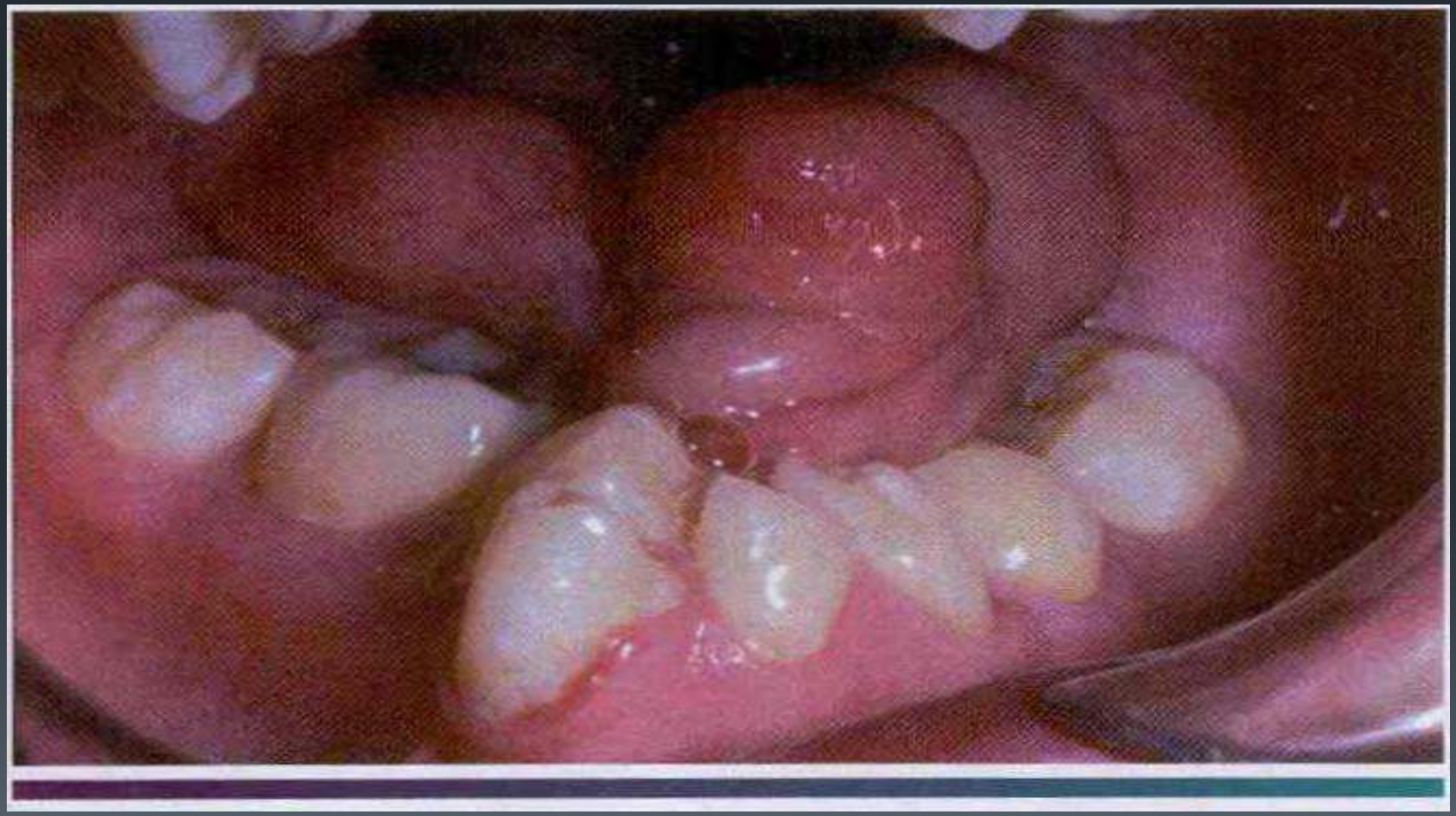

Microglossia. Associated constriction of the maxillary arch in the same patient.

ANKYLOGLOSSIA (TONGUE-TIE):

Ankyloglossia characterized by an abnormally **short and anteriorly positioned lingual frenum** that results in severly restricted tongue movements and impaired speech.

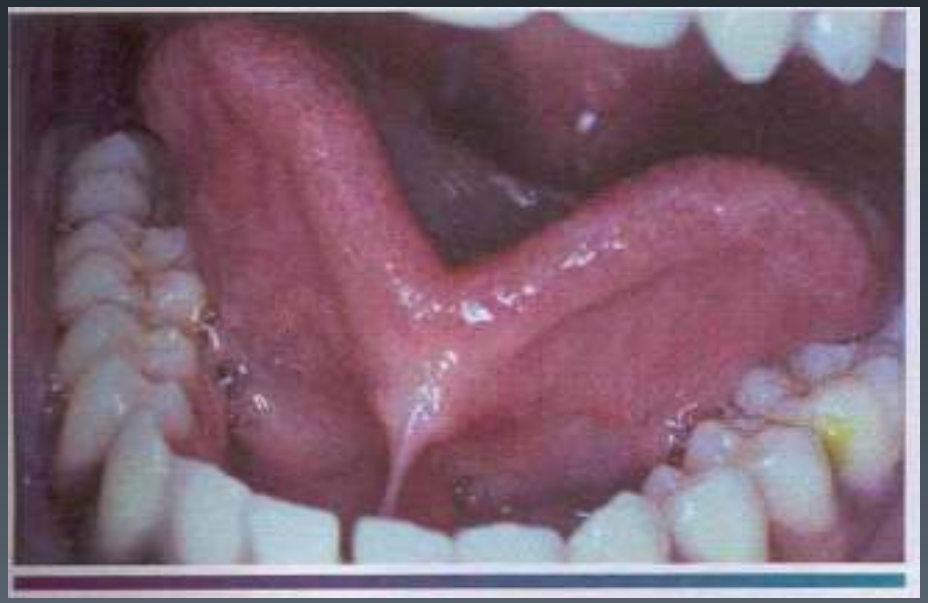

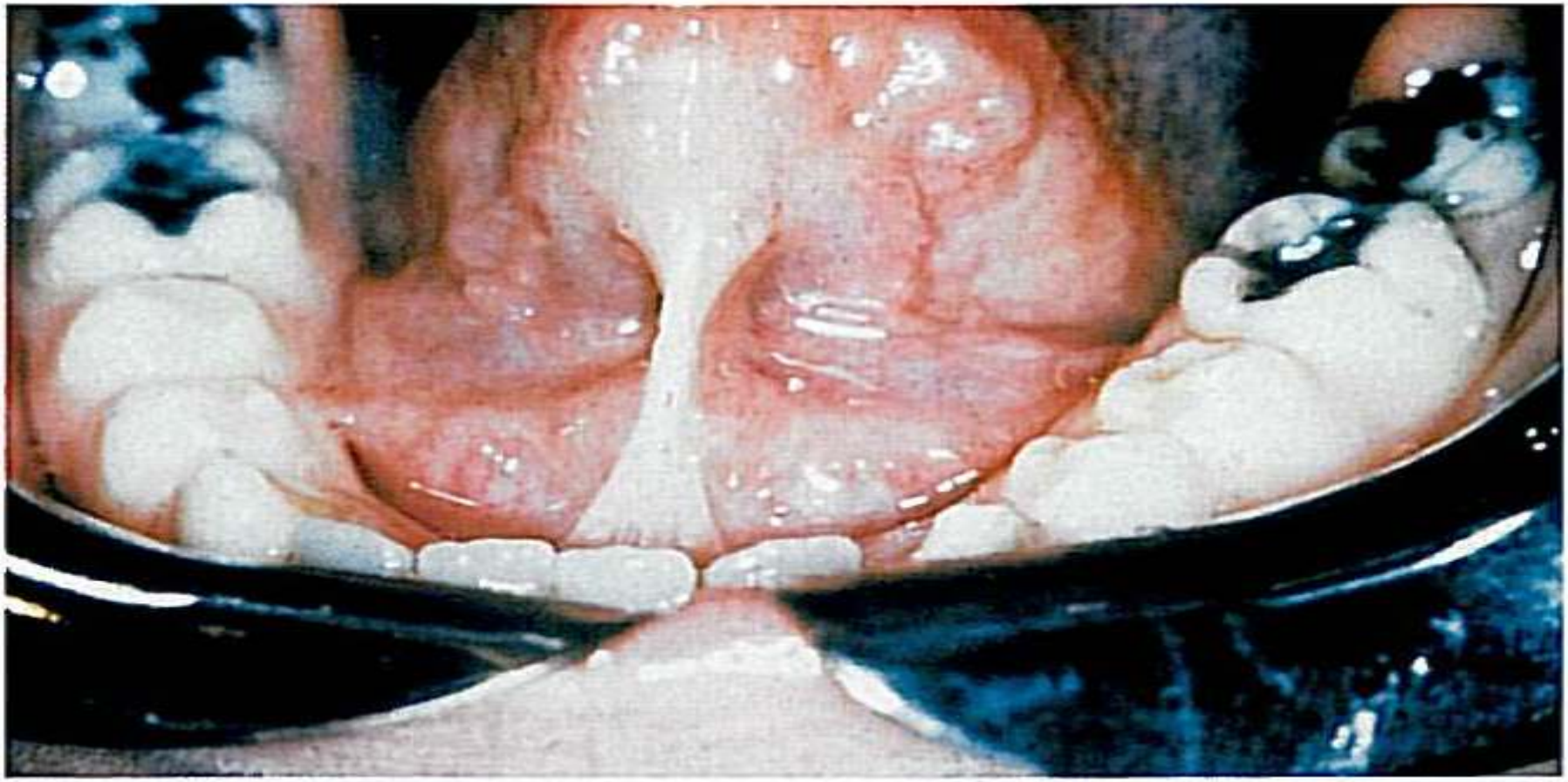

FIGURE 1-50

Ankyloglossia. The tongue of the patient has reduced mobility caused by the large band of fibrous tissue extending from the ventral tongue to the lingual gingiva of the anterior mandible.

Lingual thyroid nodule:

- A lingual thyroid nodule represents a thyroid remnant in the region of the thyroid gland's origin.

Histopathology: most cases are composed of normal mature thyroid tissue although embryonic or fetal thyroid tissue may be seen.

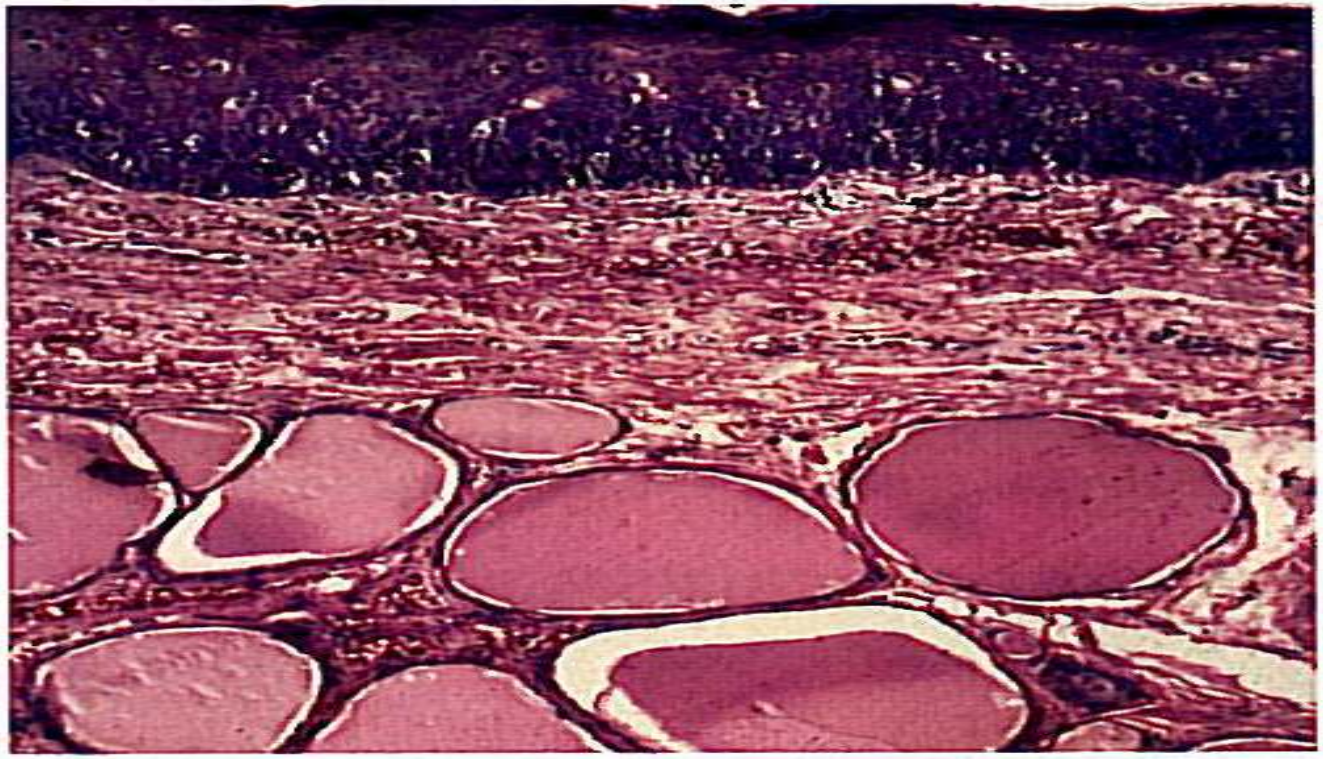

IGURE 1-55
Normal thyroid tissue in a lingual thyroid nodule of the posterior ongue.

Lingual thyroid showing thyroid acini in the submucosa.

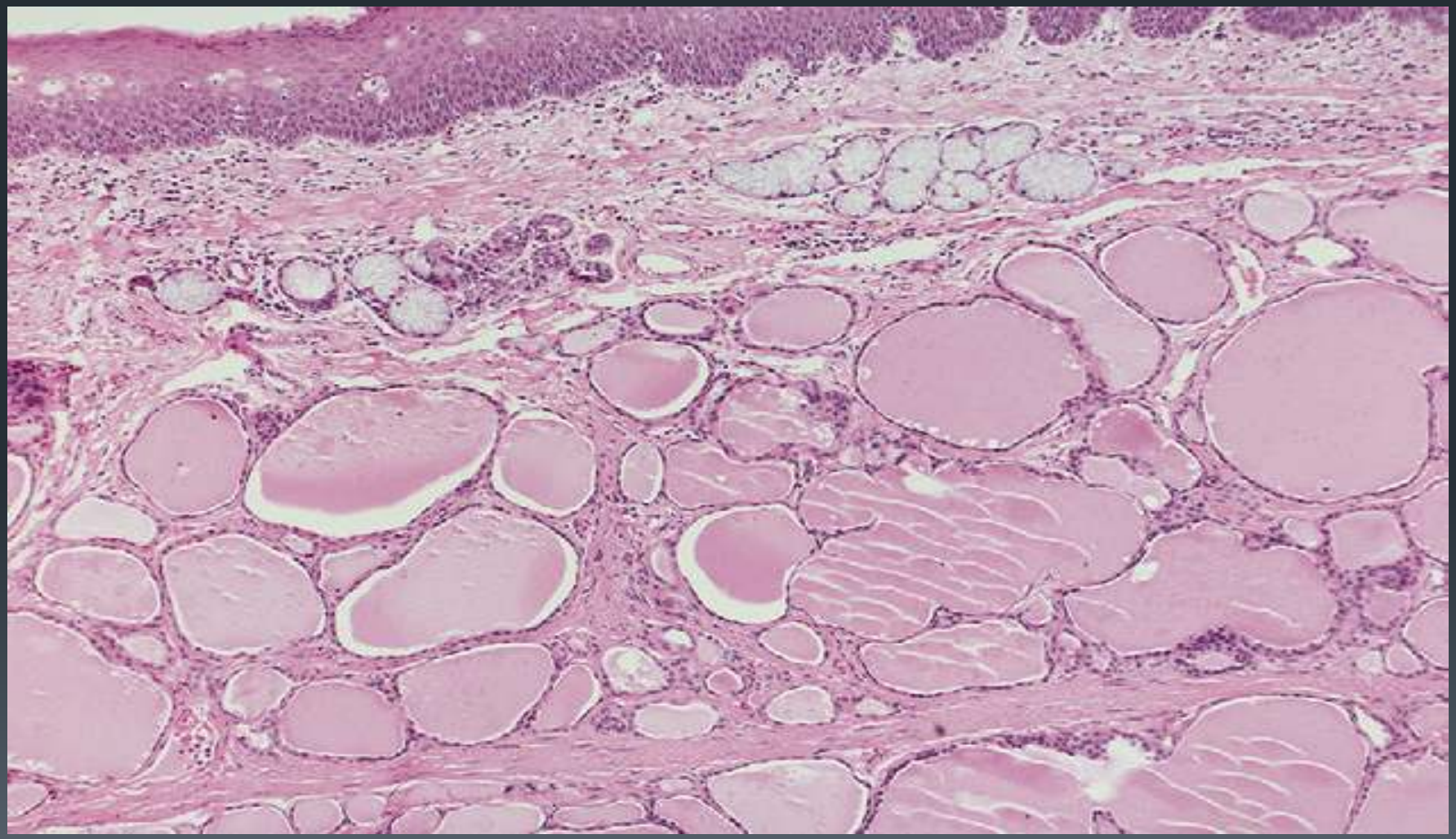

HAIRY TONGUE (BLACK HAIRY TONGUE)

- marked accumulation of keratin on the filiform papillae of the dorsal tongue, resulting in a hair like appearance.
- The condition apparently represents an increase in keratin production or a decrease in normal keratin desquamation.
- Hairy t

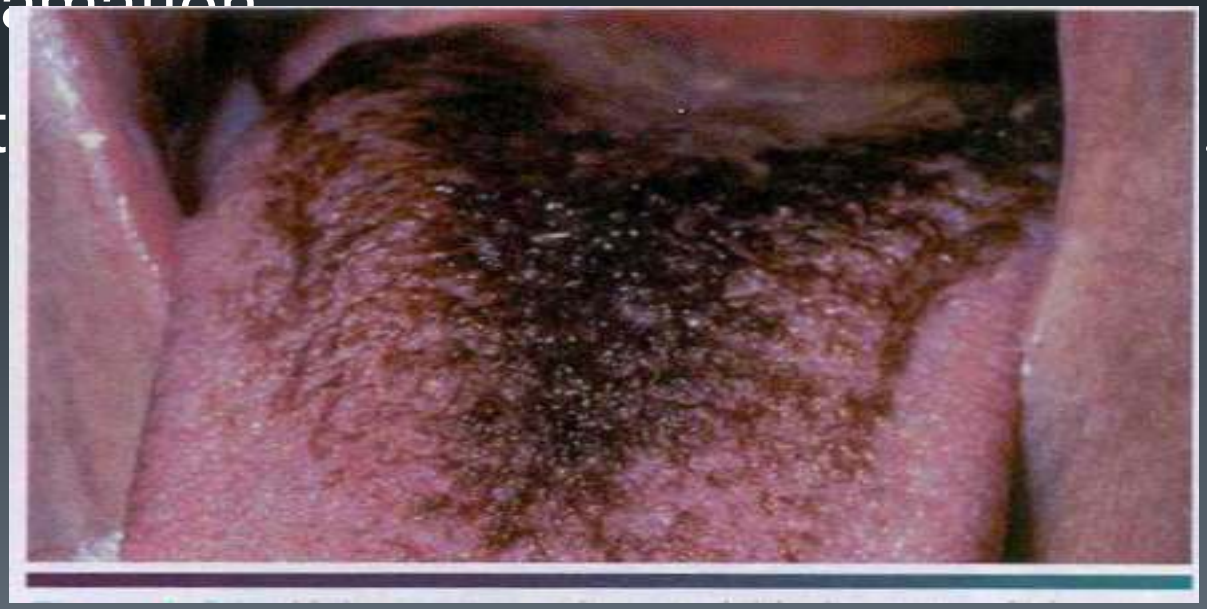

Although the cause is uncertain, many affected people are heavy smokers. Other possible associated factors include the following:

- Antibiotic therapy.
- Poor oral hygiene.
- General debilitation .
- Radiation therapy.
- Use of oxidizing mouthwashes or antacids.
- Overgrowth of fungal or bacterial organisms.

Hairy tongue

Hairy tongue. Elongation and marked hyperkeratosis of the filiform papillae. with bacterial accumulation on the surface.

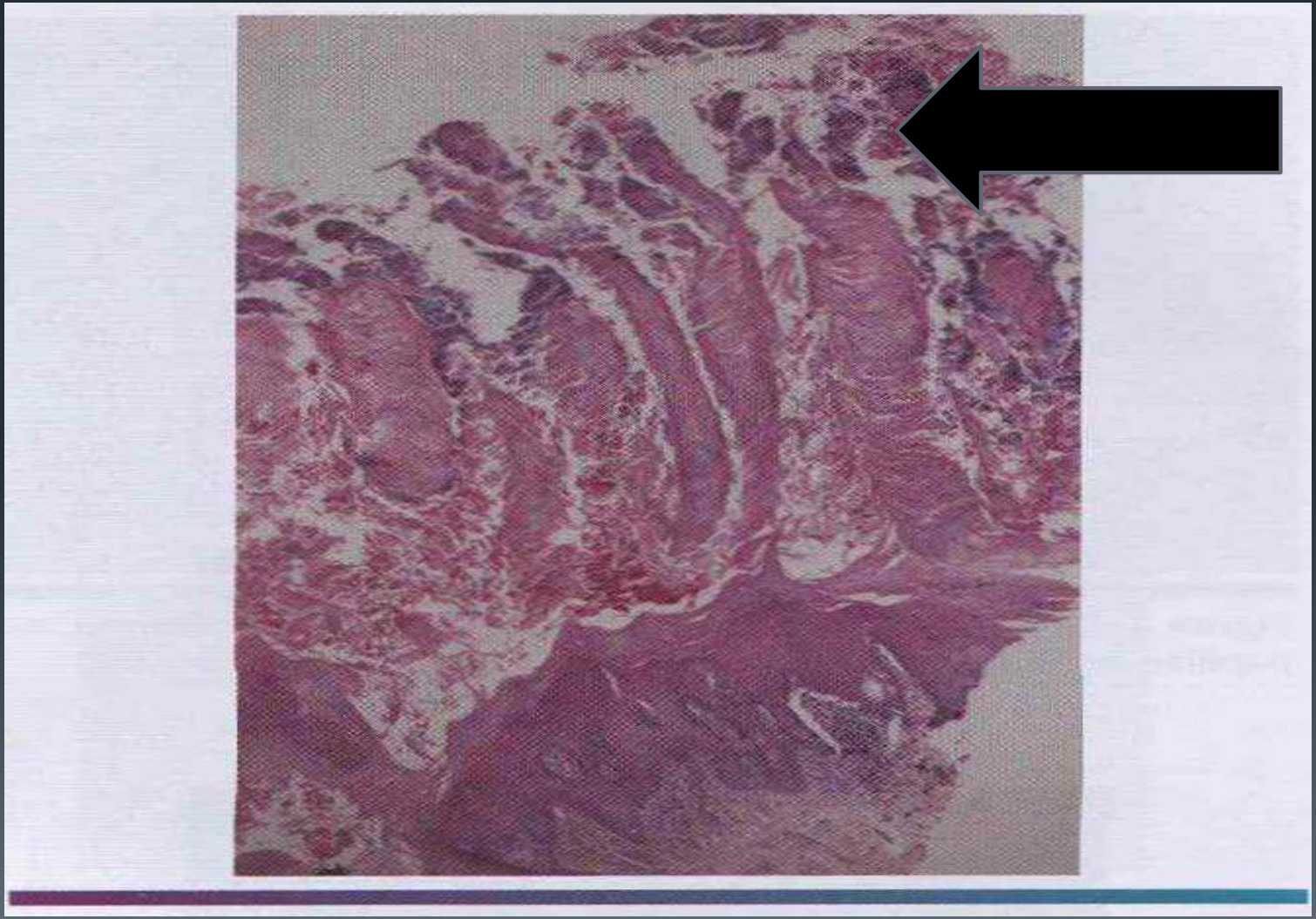

VARICOSITIES (VARICES):

- abnormally dilated and tortuous veins.
- Age appears to be an important etiologic factor because varices are rare in children but common in older adults.
- Oral varices have not been associated with systemic hypertension or other cardiopulmonary diseases.

Histopathologic Features:

- a dilated vein. The wall of which shows little smooth muscle and poorly developed elastic tissue, If secondary thrombosis has occurred, the lumen may contain concentrically layered zones of platelets and erythrocytes *(lines of Zahn).*

CALIBER-PERSISTENT ARTERY

- common vascular anomaly in which a main arterial branch extends up into the superf cial submucosal tissues without a reduction in its diameter.
- similar to oral varices. caliber-persistent arteries are seen more frequently in older adults.

Caliber-persistent artery lesion on the upper labial mucosa.

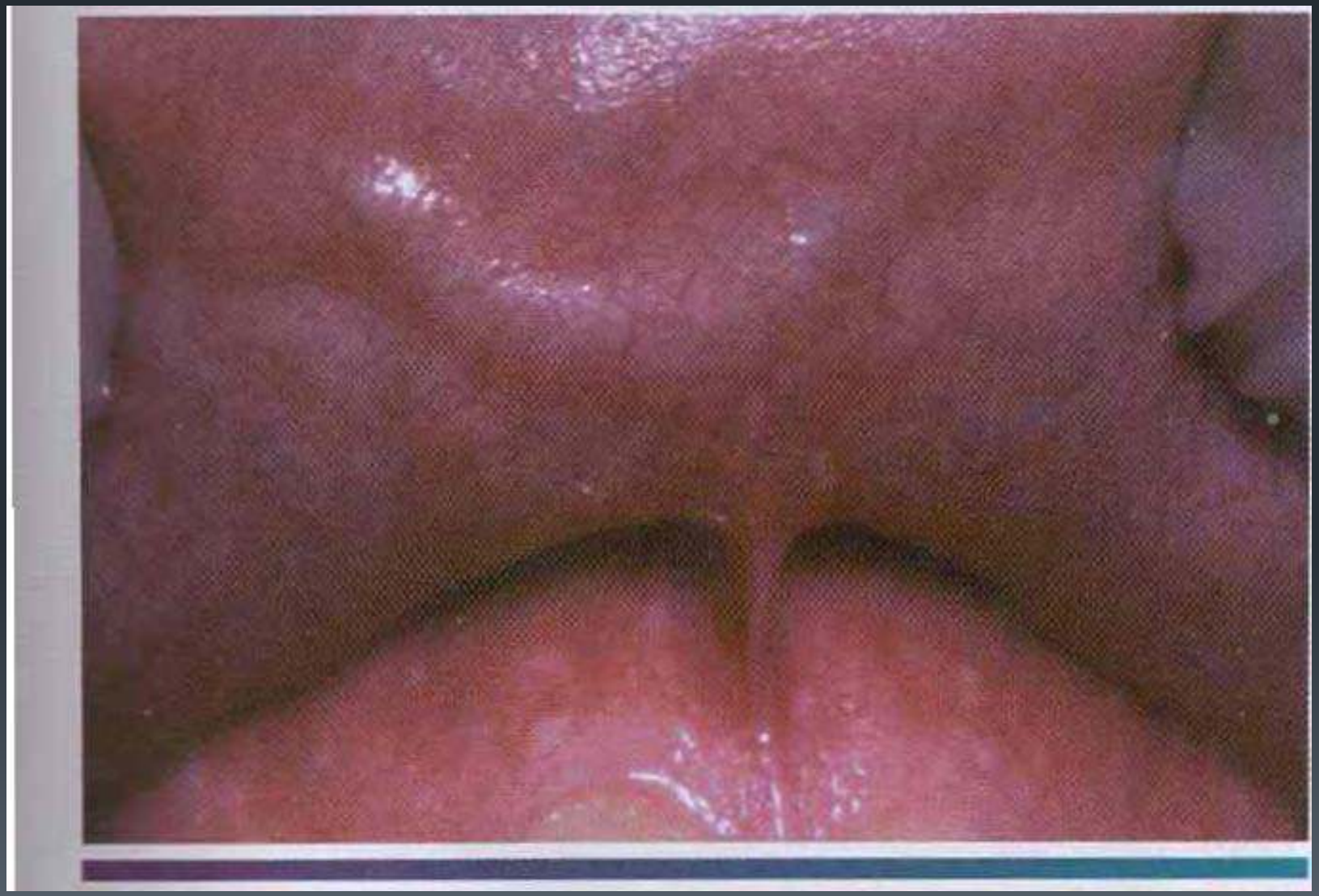

Caliber-persistent artery. Thick-walled artery located just beneath the mucosal surface.

LATERAL SOFT PALATE FISTULAS:
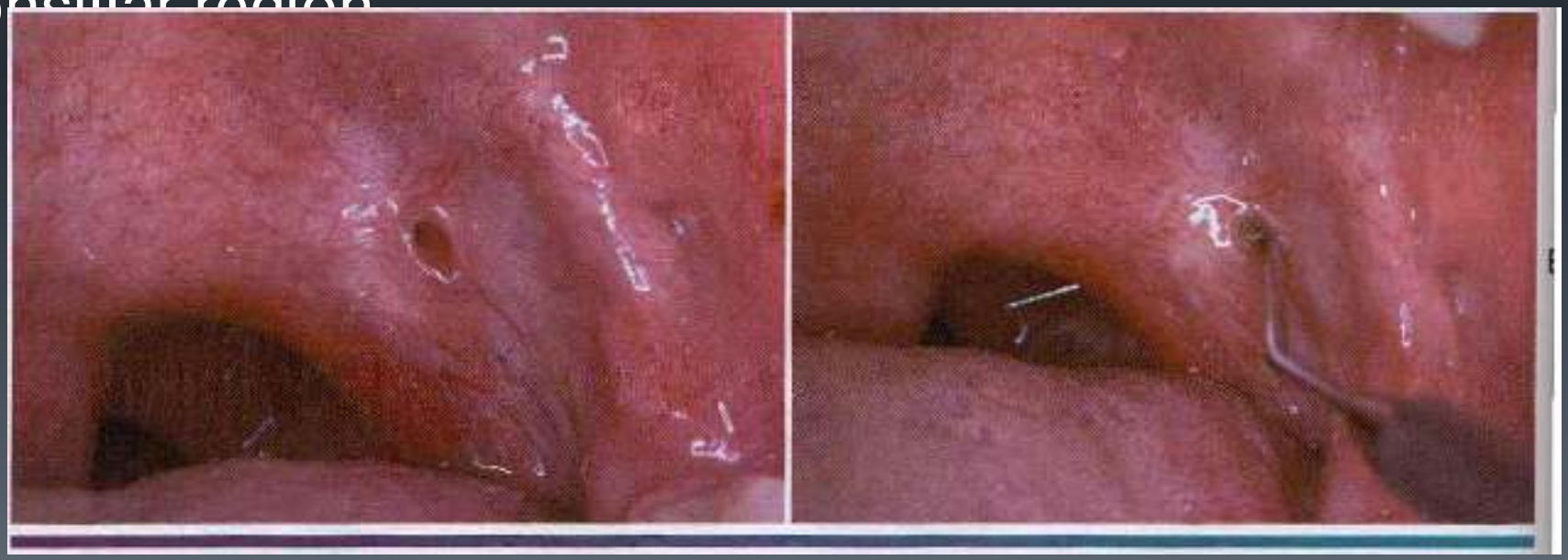
Lateral soft palate fistulas are rare anomalies of uncertain pathogenesis. Many cases appear to be congenital possibly related to a defect in the development of the second pharyngeal pouch. Some fistulas may be the result of infection or surgery of the tonsillar region.